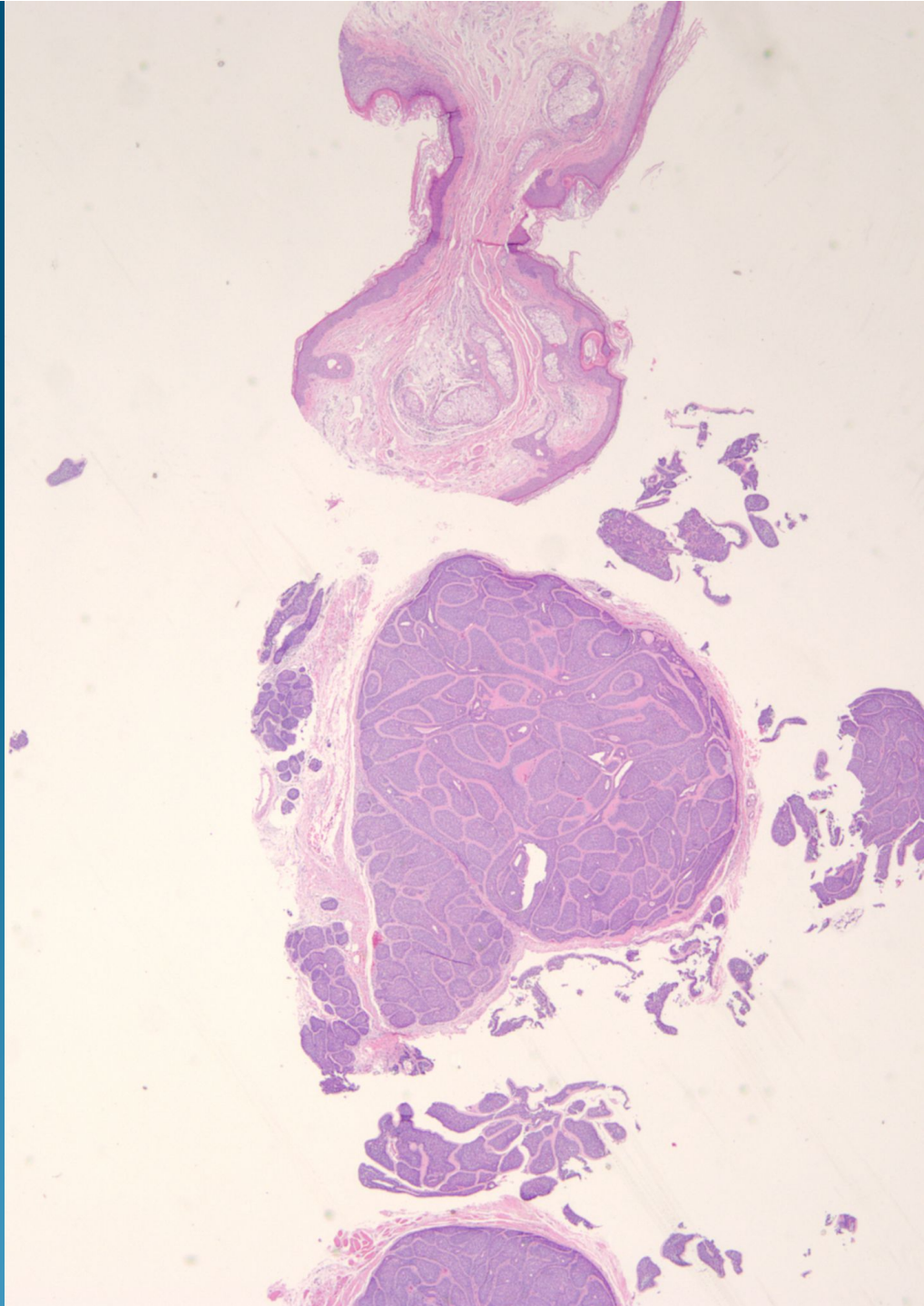
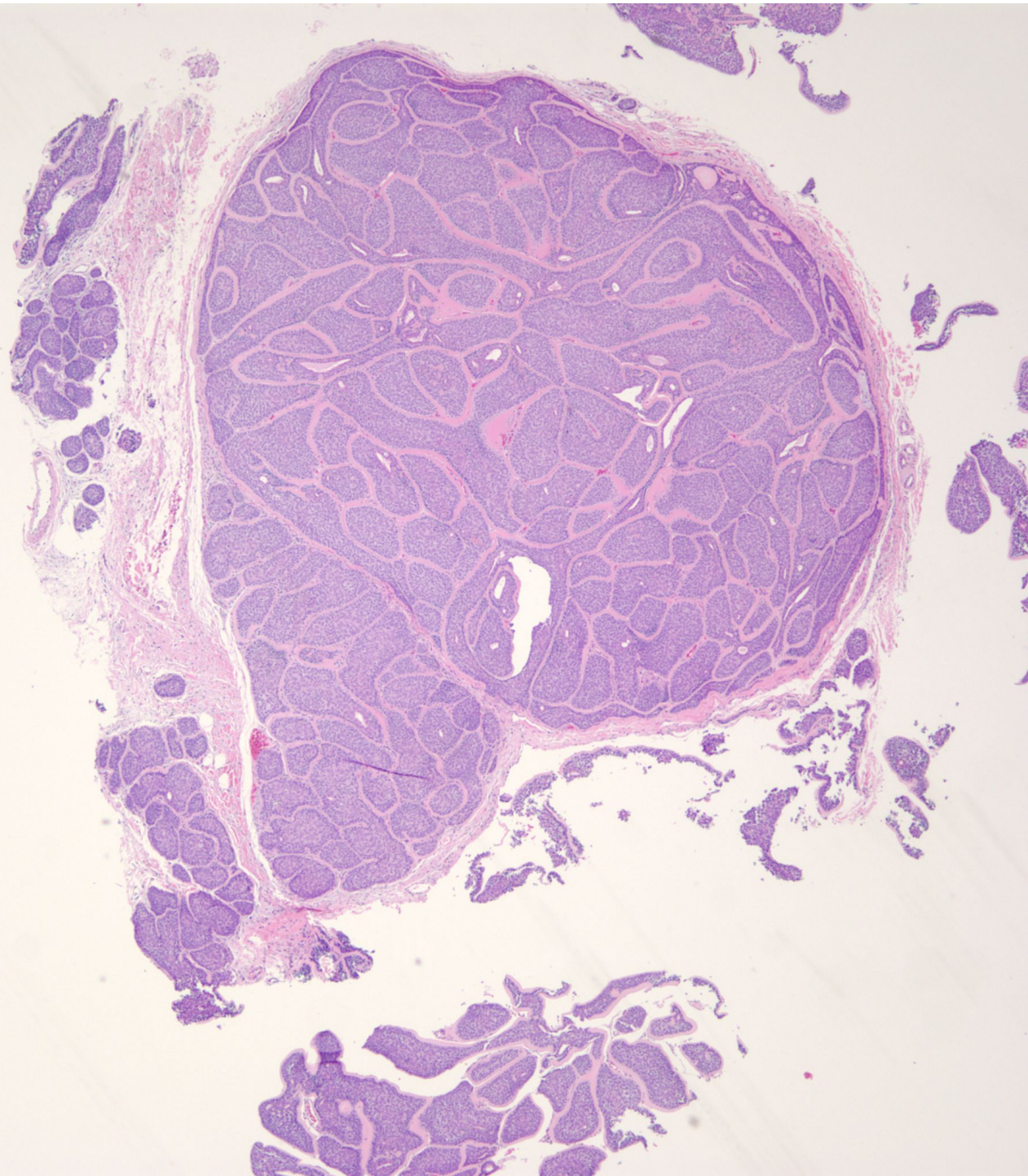
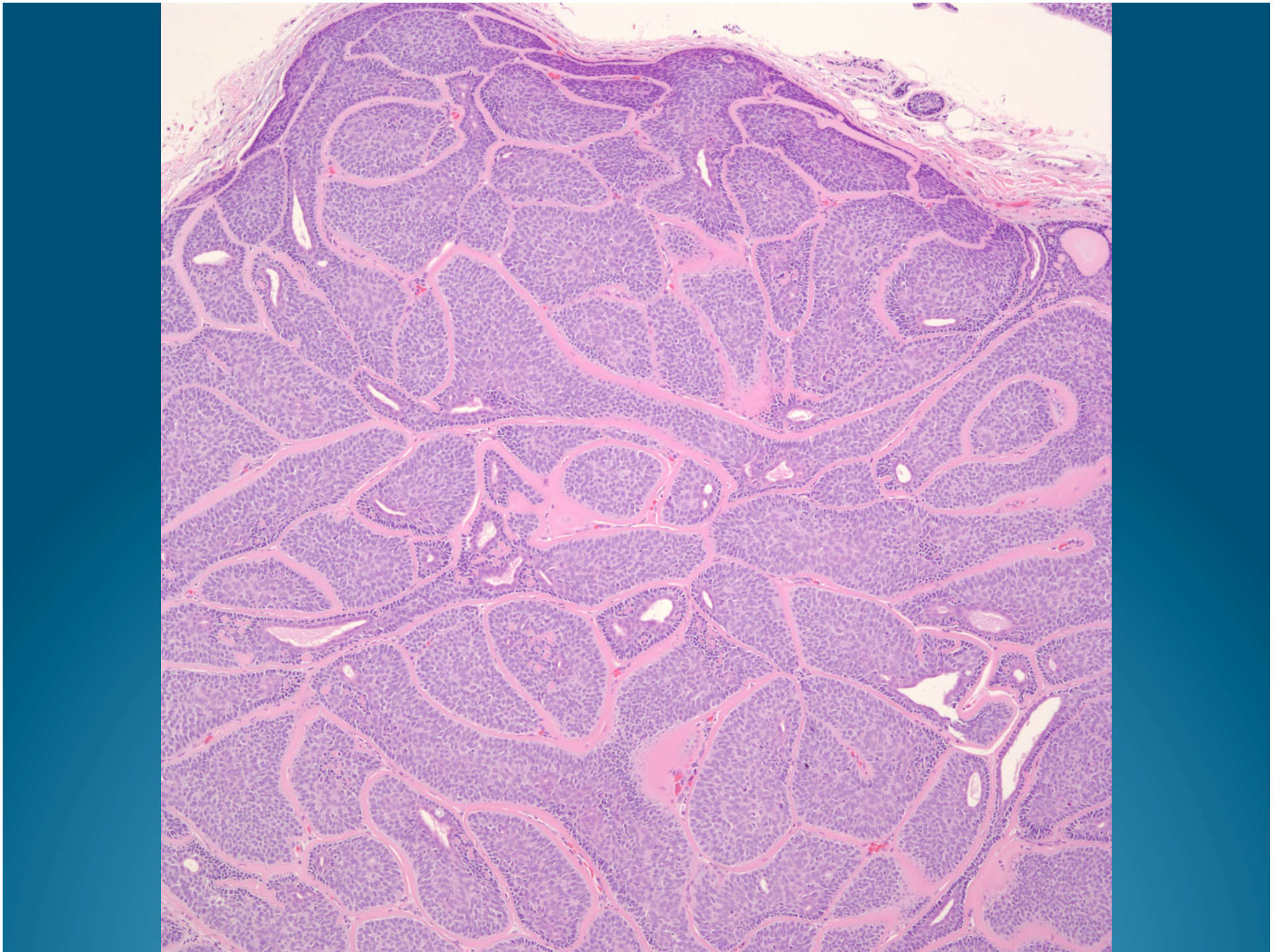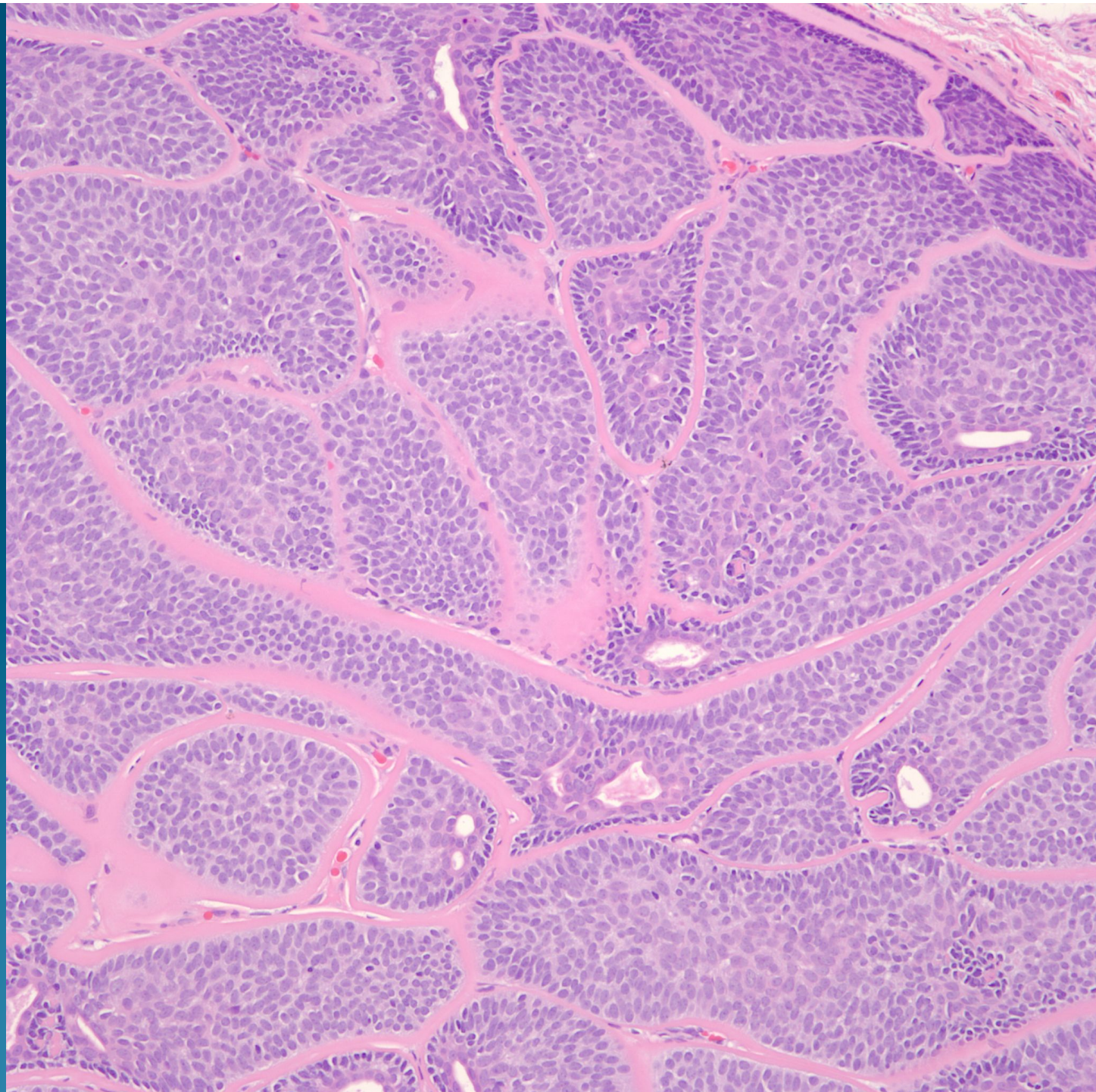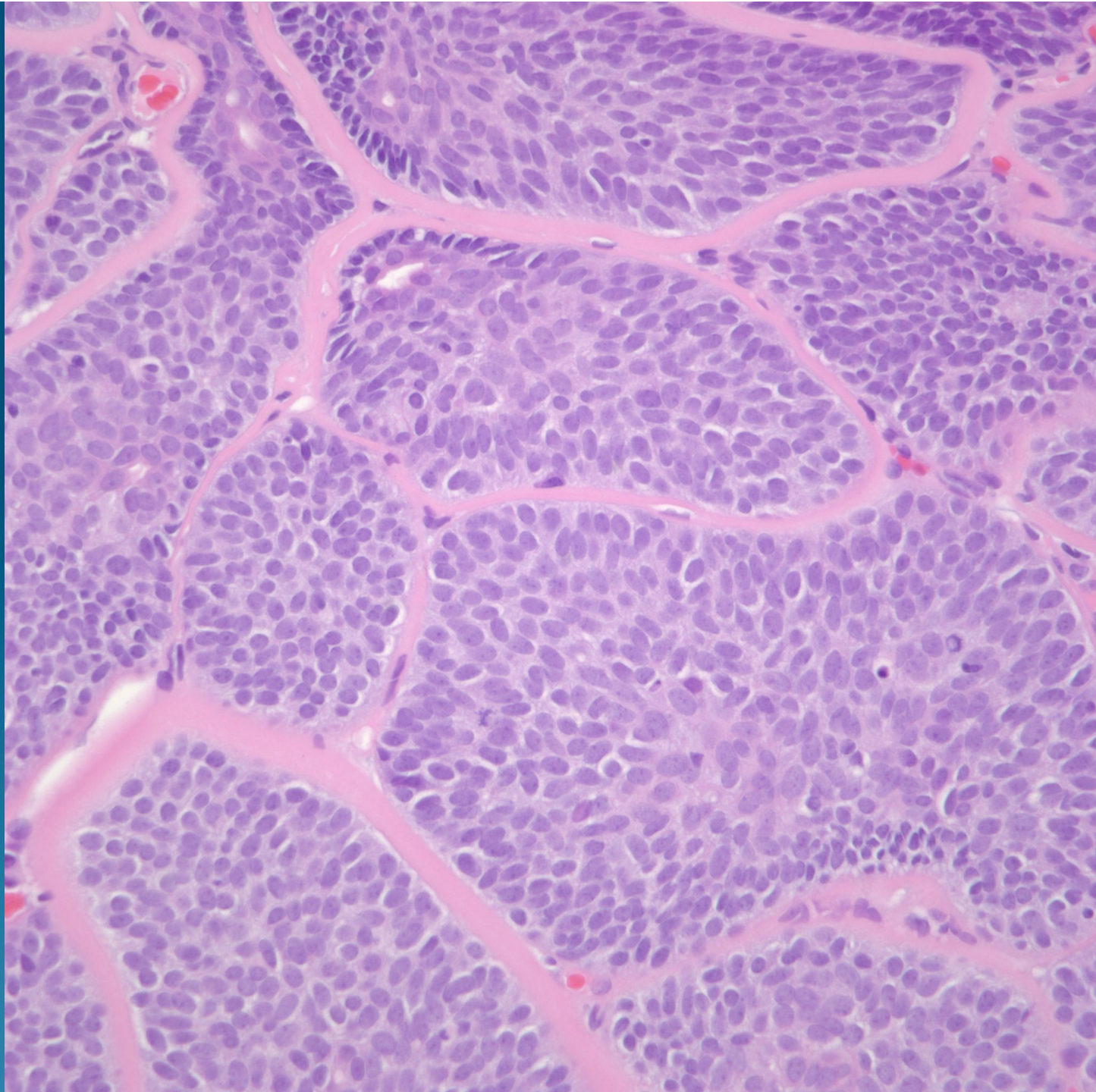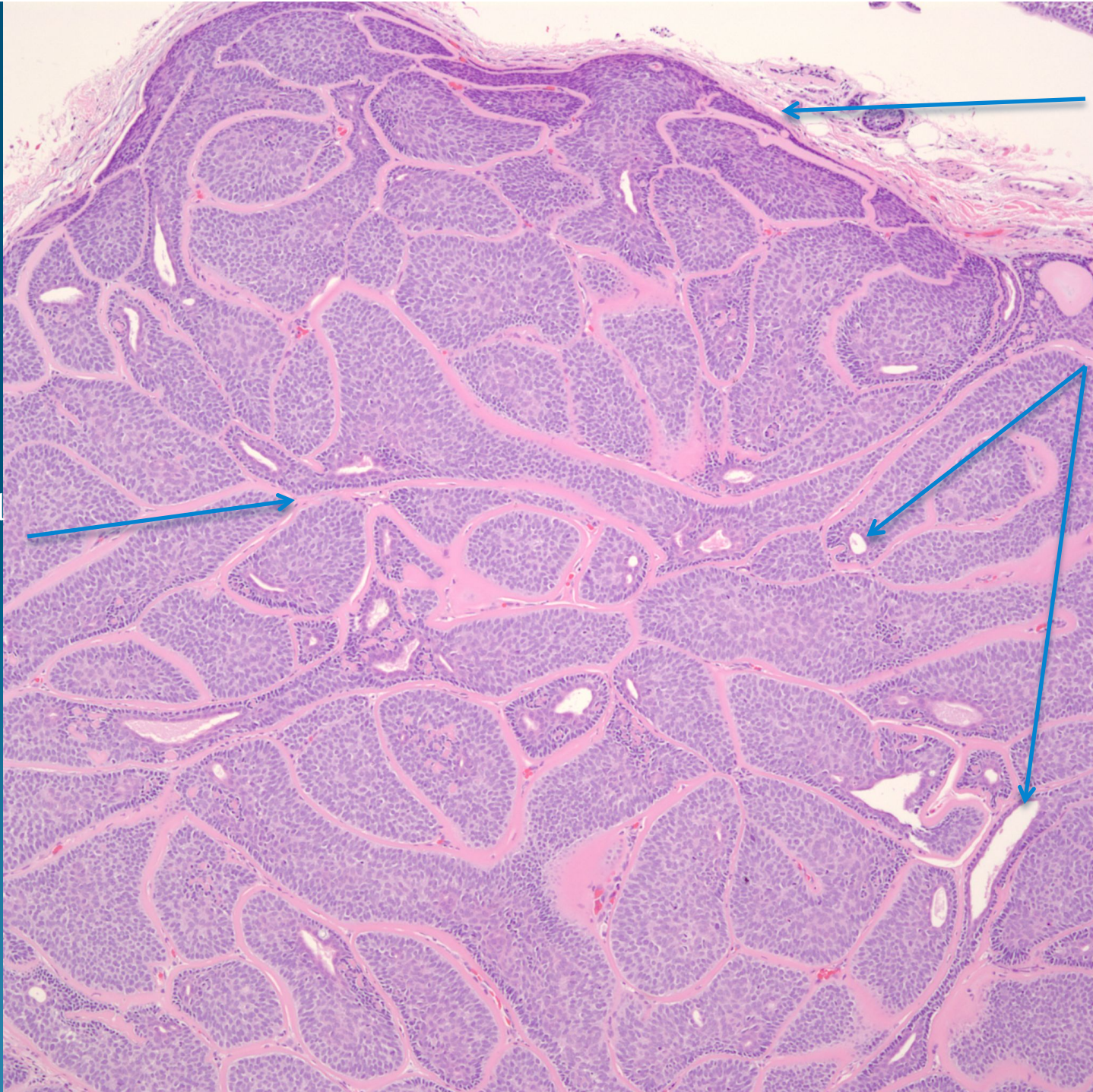
What is the best diagnosis?

- A. Nodular basal cell carcinoma
- B. Cylindroma
- C. Spiradenoma
- D. Merkel cell carcinoma
- E. Adenoid Cystic Carcinoma

Cylindroma

Jig-saw
Puzzle
Architec-
ture

Hyalinized
stroma



Well
Circum-
scribed

Ductal
Differen-
tiation